

Module 9 LO4

Appendicular Musculature: Upper Limb Muscles

Dr. Lisa Brinn

lbrinn@fiu.edu

[Link to video recording](#)

Rules to keep in mind about muscles

1. Muscles always pull towards the origin
2. Origin for appendicular muscles is always proximal
3. Muscles always cross at least 1 joint
 - Some cross two joints
4. Muscles can't have an origin and an insertion on the same bone
5. Muscles in the same compartment will probably have the same function

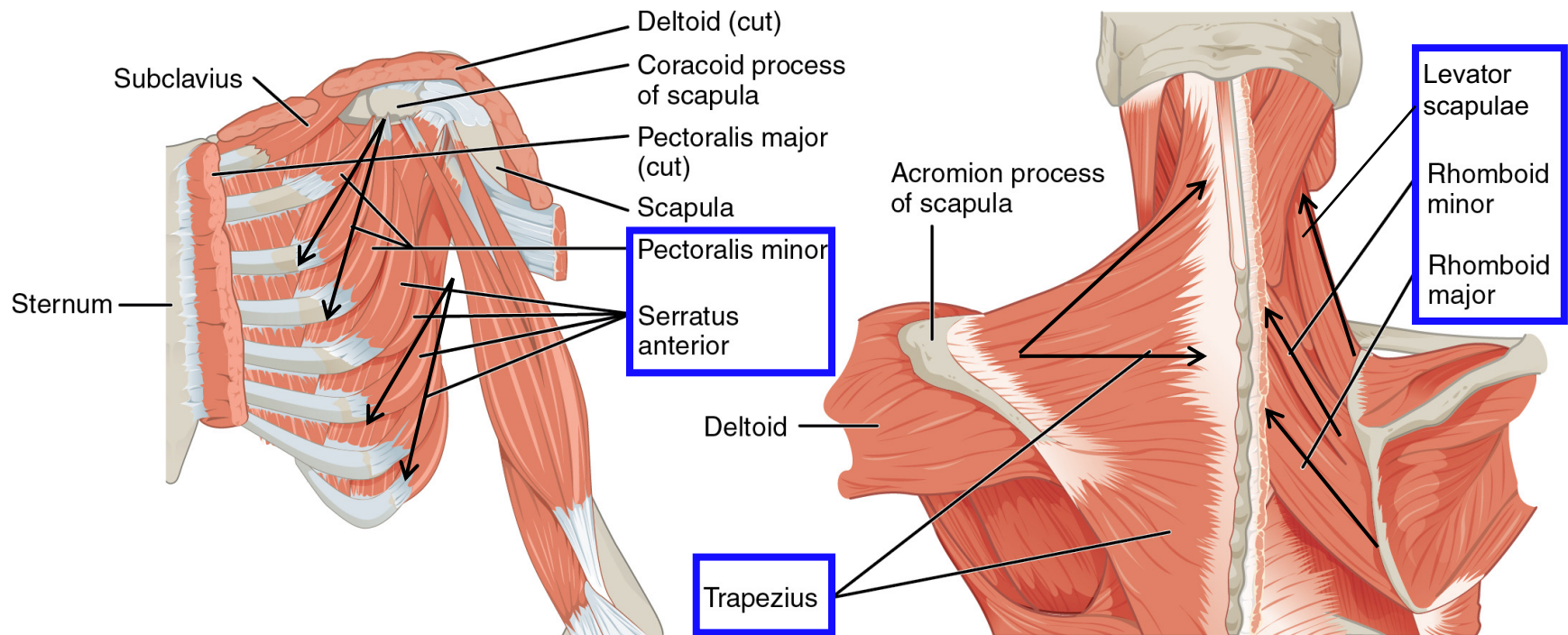
4. Appendicular Musculature: Upper Limb

- a. Group 1:** move the pectoral girdle
- b. Group 2:** move the arm at the shoulder
- c. Group 3:** move the forearm at the elbow
- d. Group 4:** move the hand at the wrist
- e. Group 5:** move the digits

a. Group 1: Move Pectoral Girdle

- **Origin:** Axial skeleton
- **Insertion:** Clavicle or Scapula

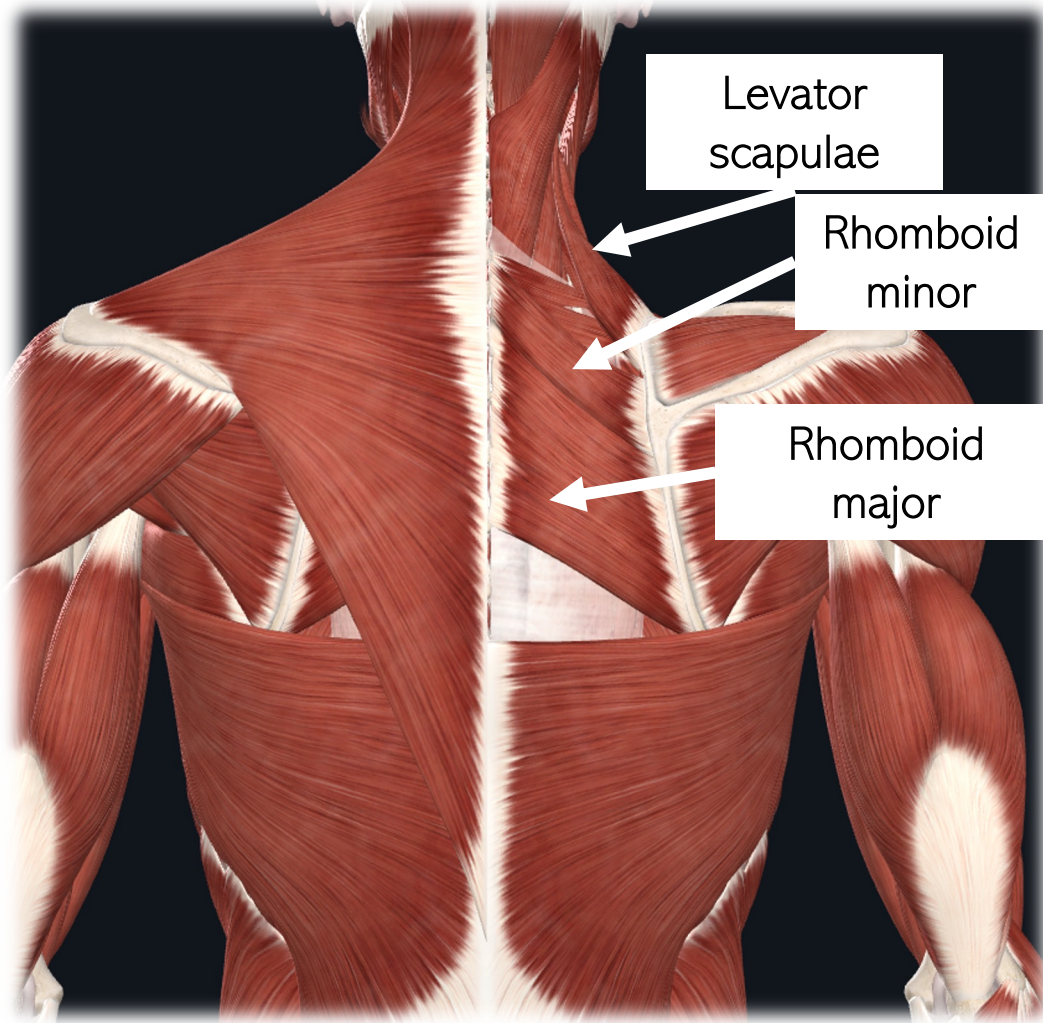
Posterior: retract the scapula
Anterior: protract the scapula



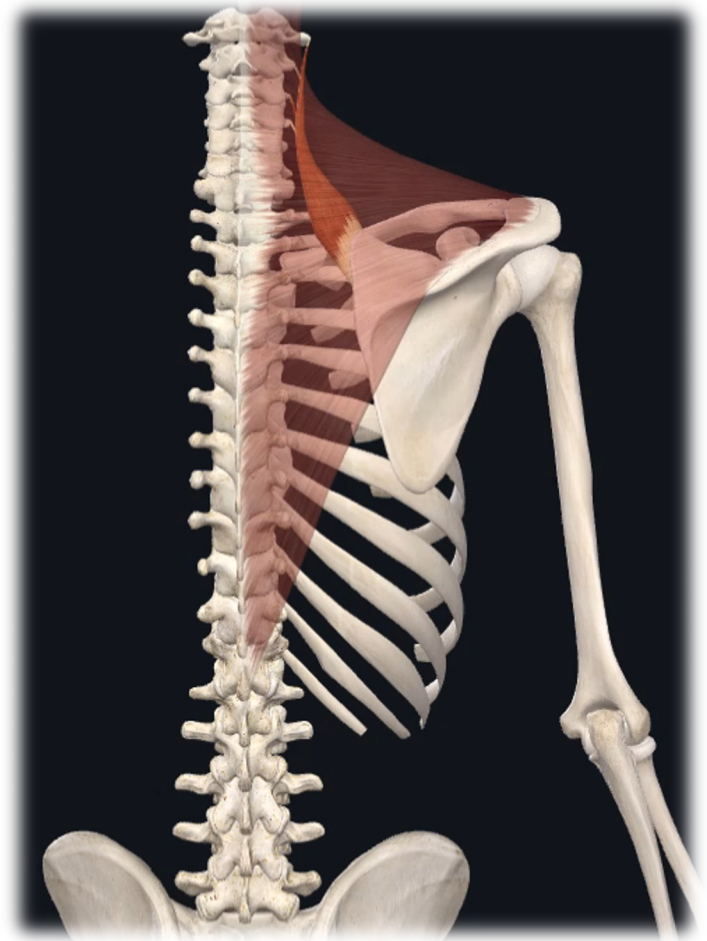
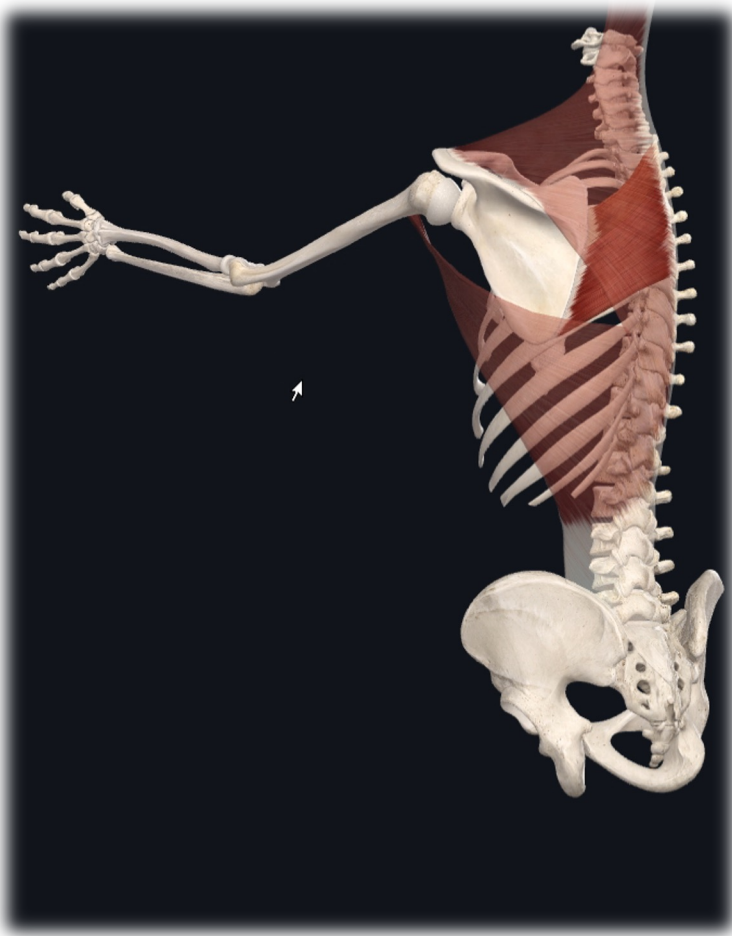
Pectoral girdle muscle (left anterior lateral view)

Pectoral girdle muscles (posterior view)

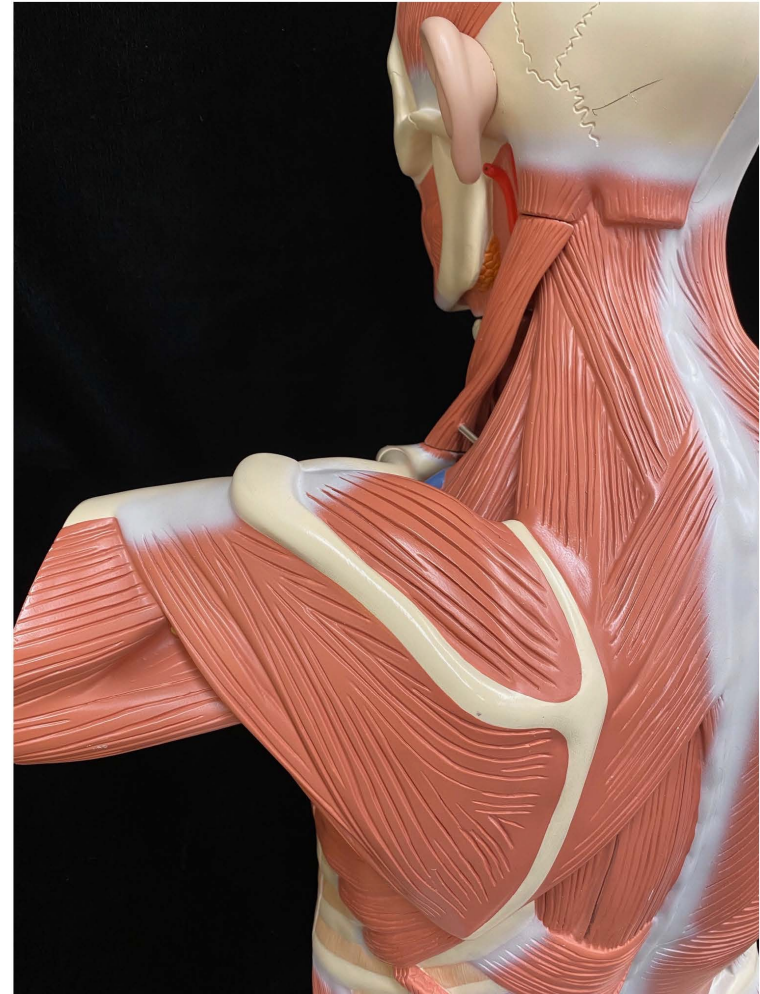
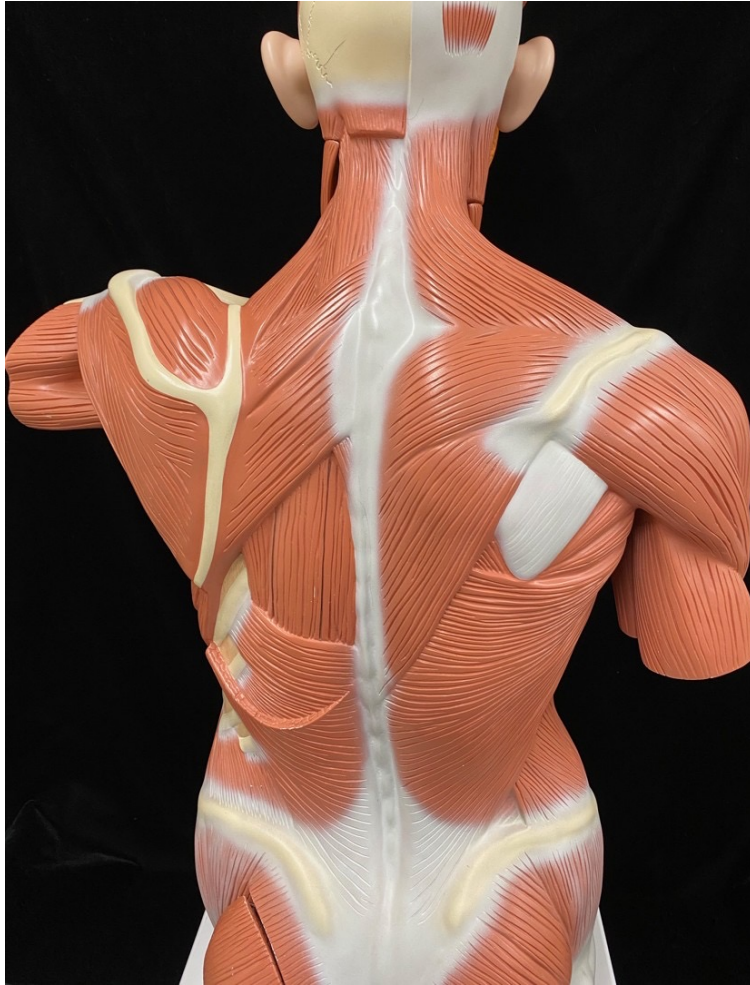Scapula Retraction and Elevation



Scapula Retraction and Elevation

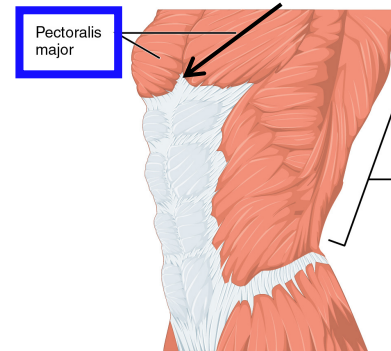
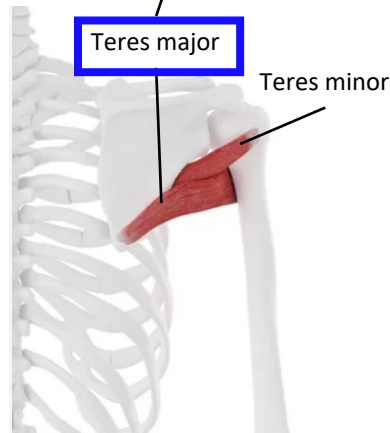
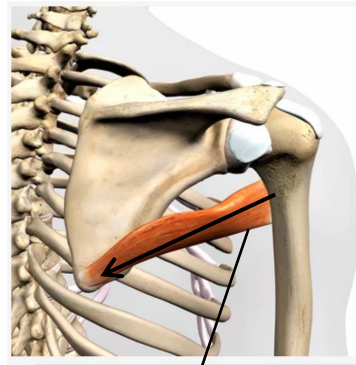
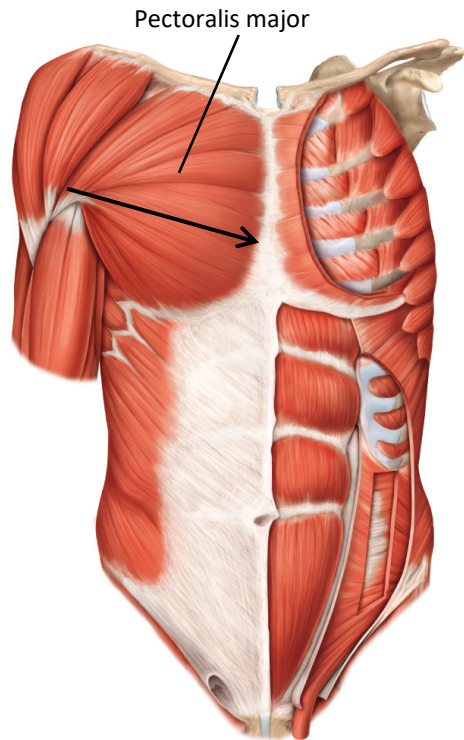


Scapula Retraction and Elevation Lab Models

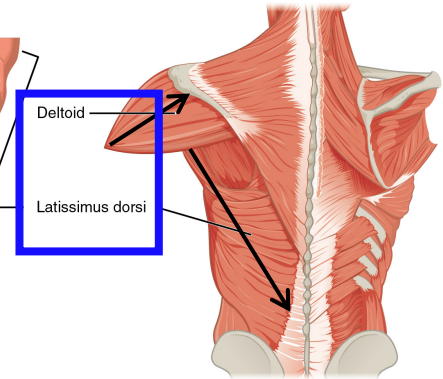


b. Group 2: Move Arm at Shoulder

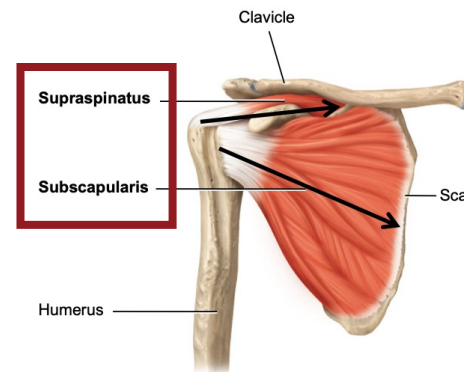
- **Origin:** Clavicle or Scapula
- **Insertion:** Humerus



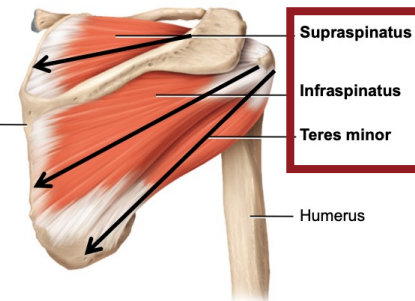
(a) Pectoralis major and latissimus dorsi (left anterior lateral view)



(b) Left deltoid and left latissimus dorsi (posterior view)



(f) Anterior deep view



(g) Posterior deep view

ANTERIOR

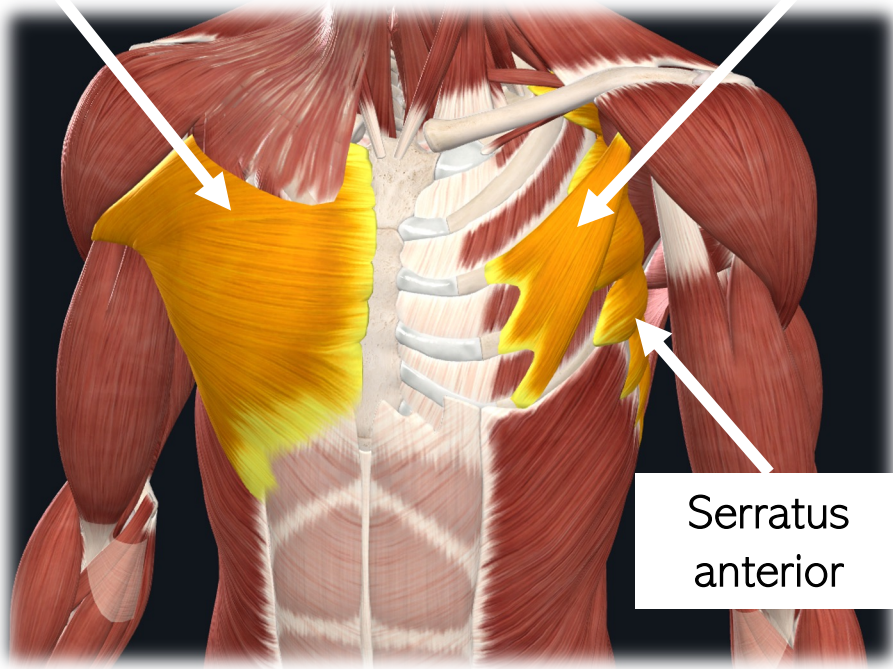
LATERAL

Pectoral Muscles

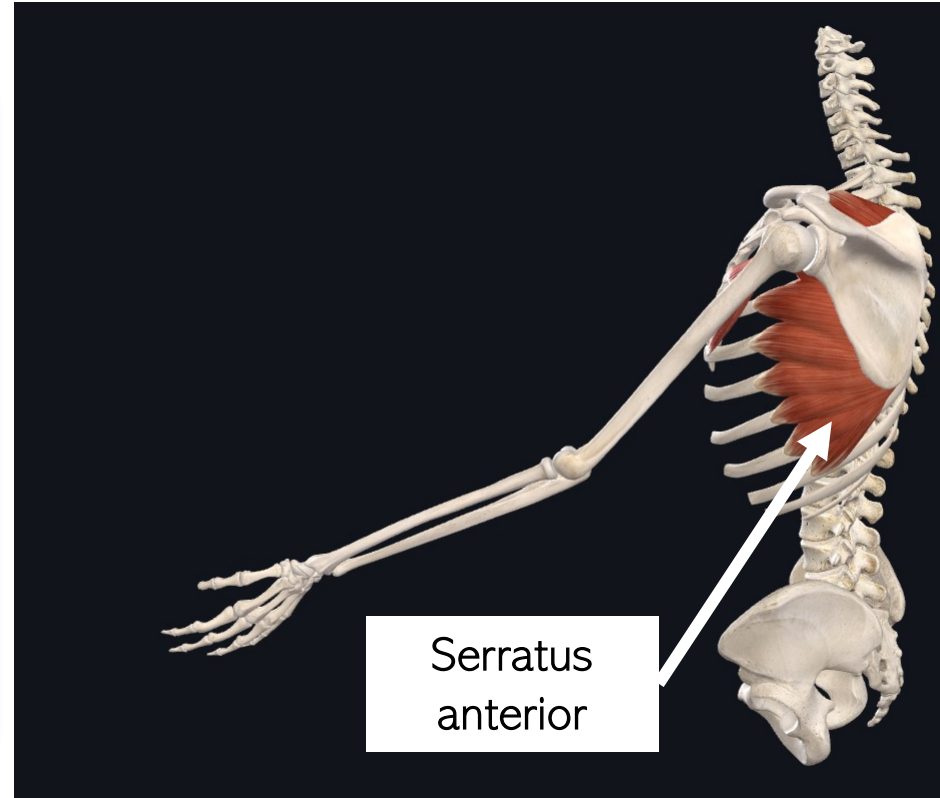
Pectoralis
major

Pectoralis
minor

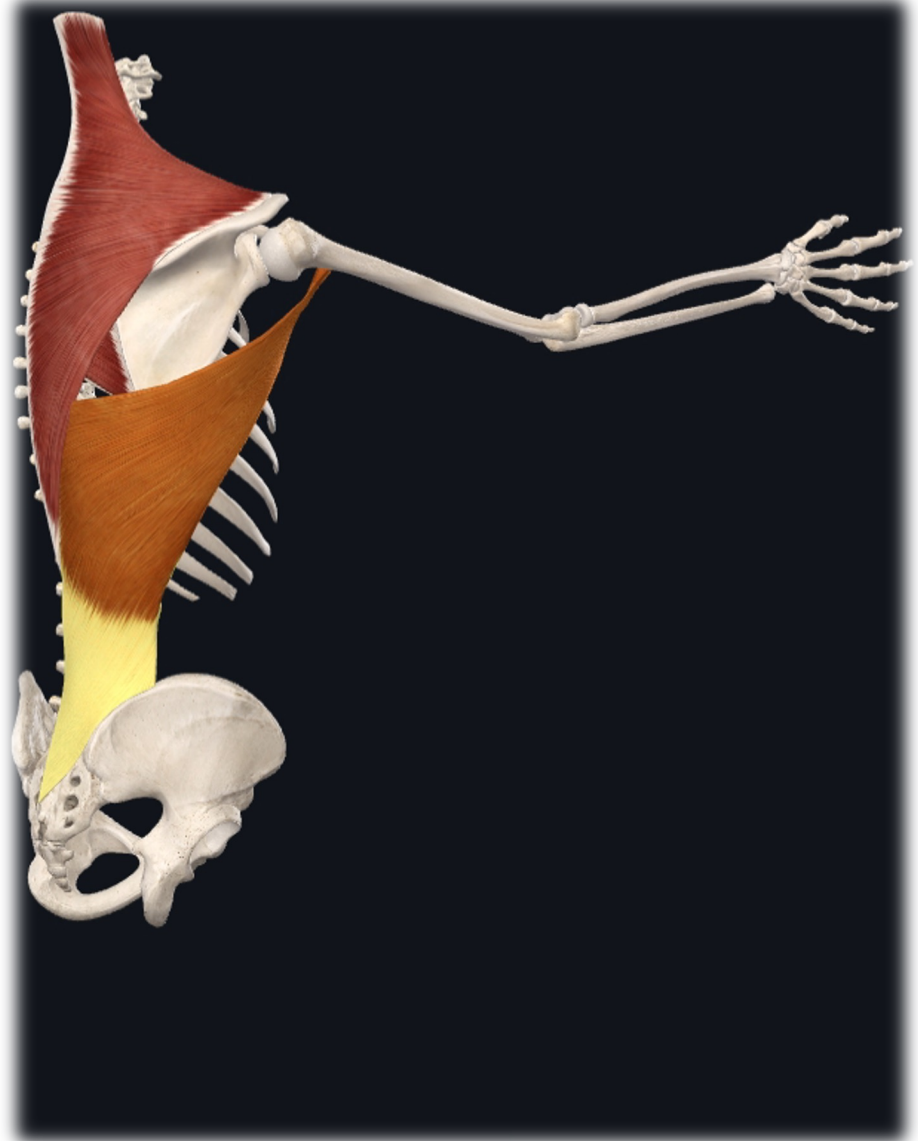
Serratus
anterior



Serratus
anterior



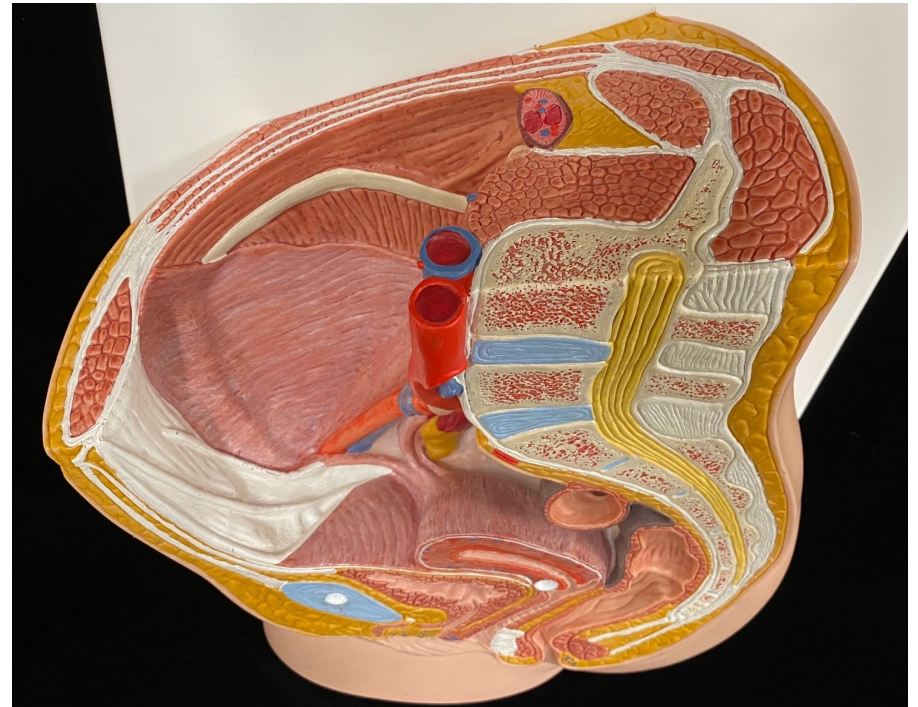
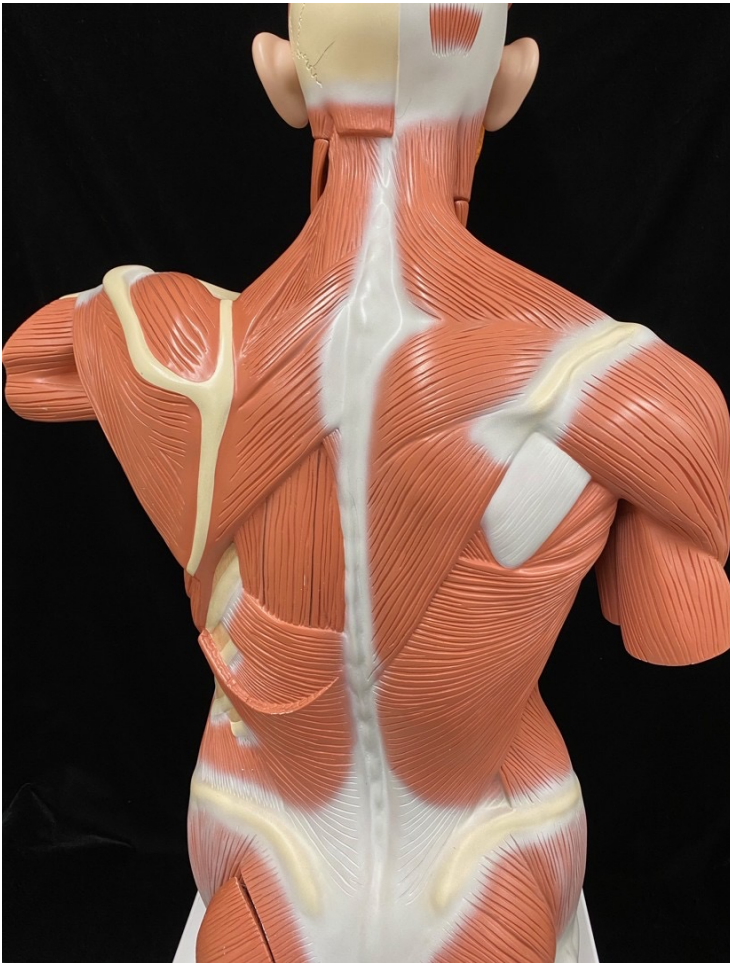Latissimus dorsi



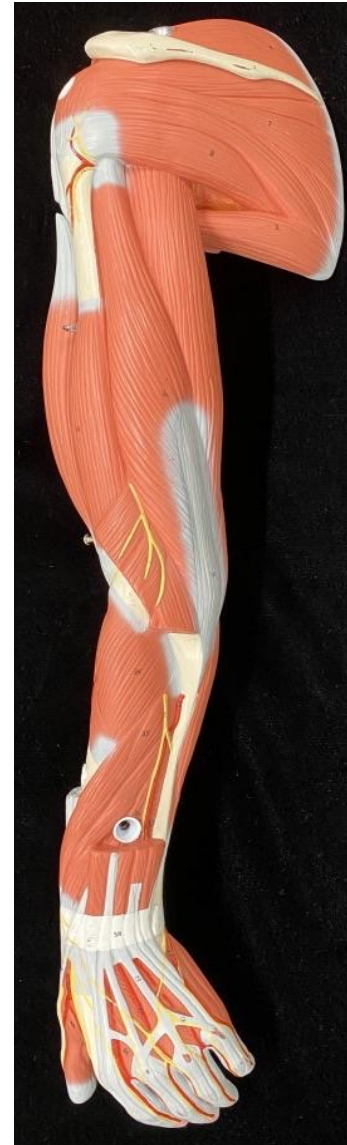
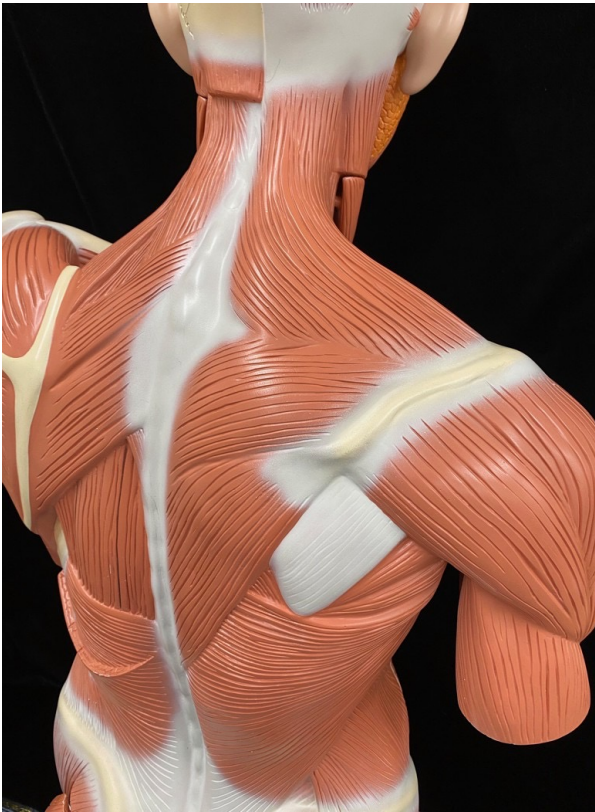
POSTERIOR

SUPERIOR

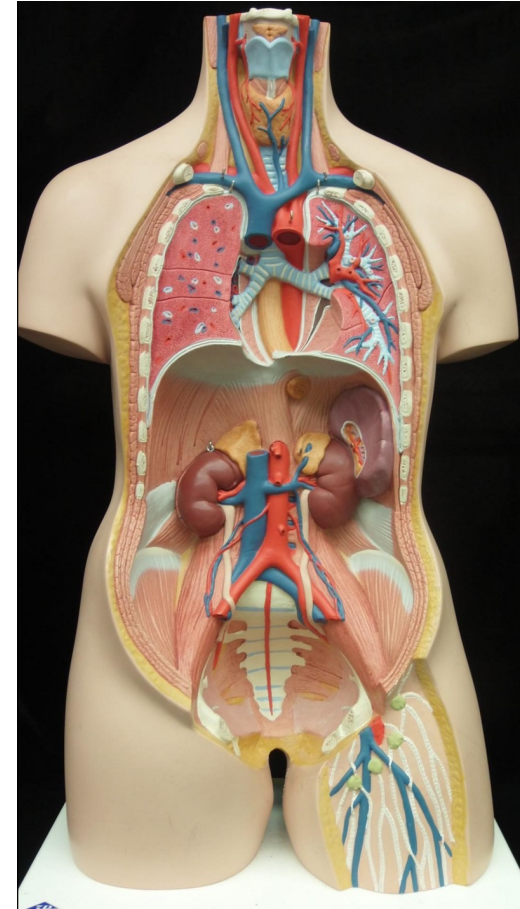
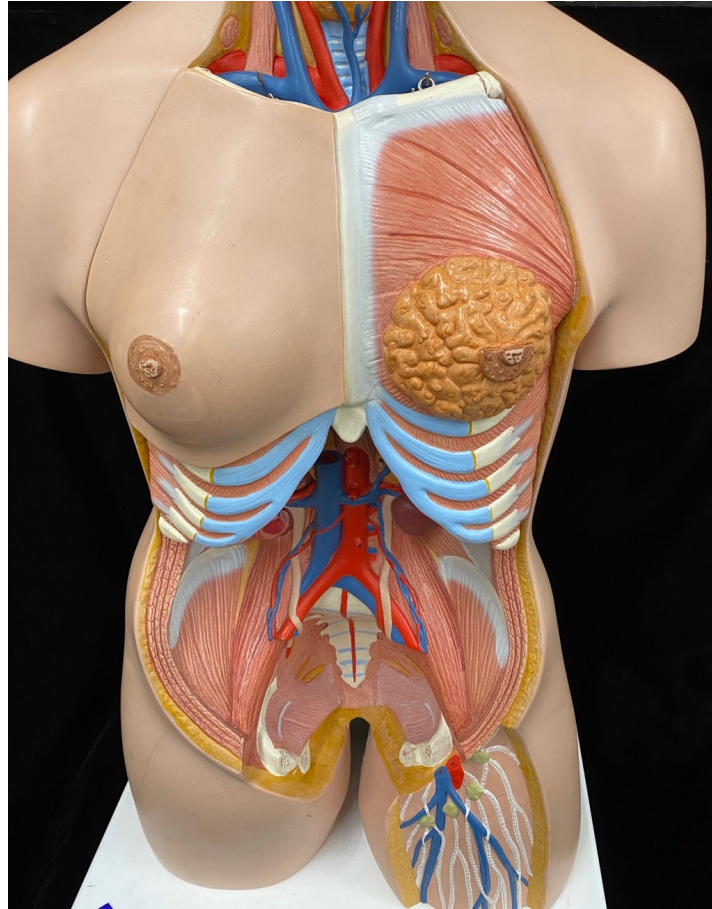
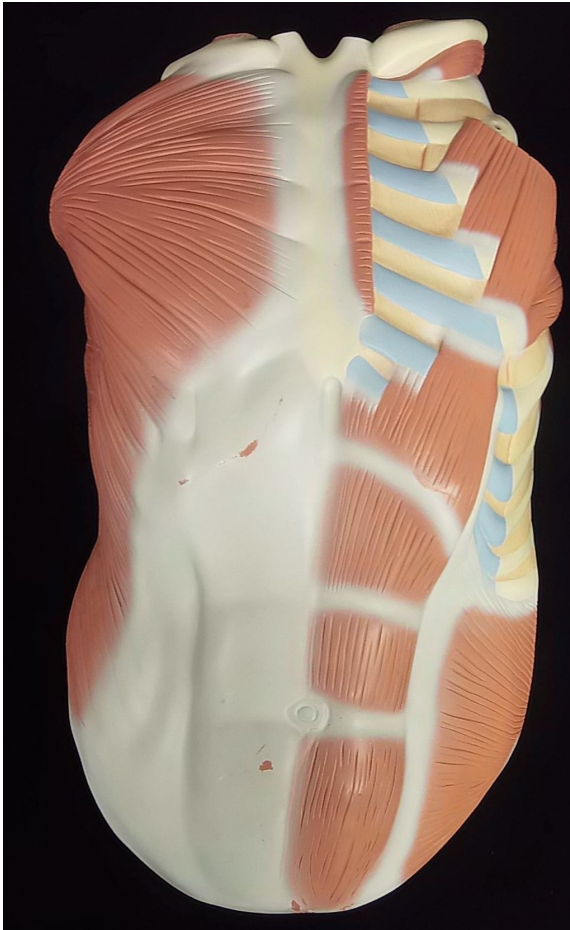
Lab Models



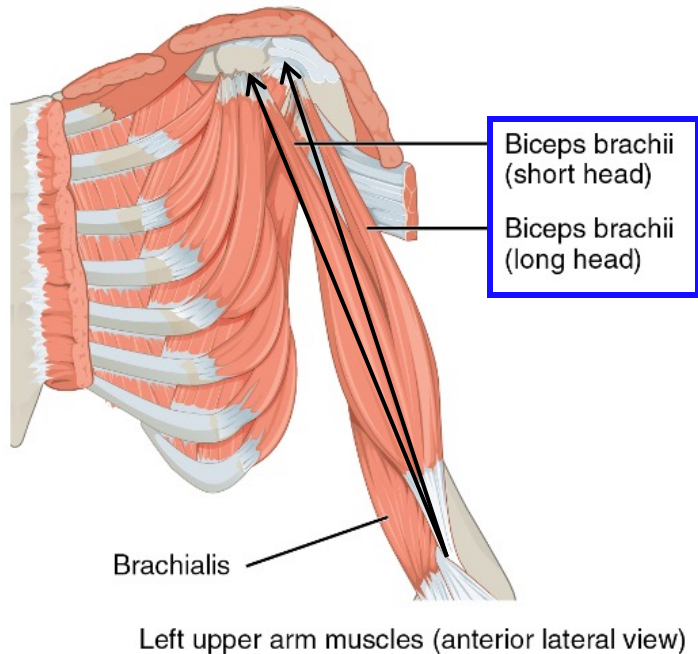
Lab Models



Pectoral Muscles Lab Models

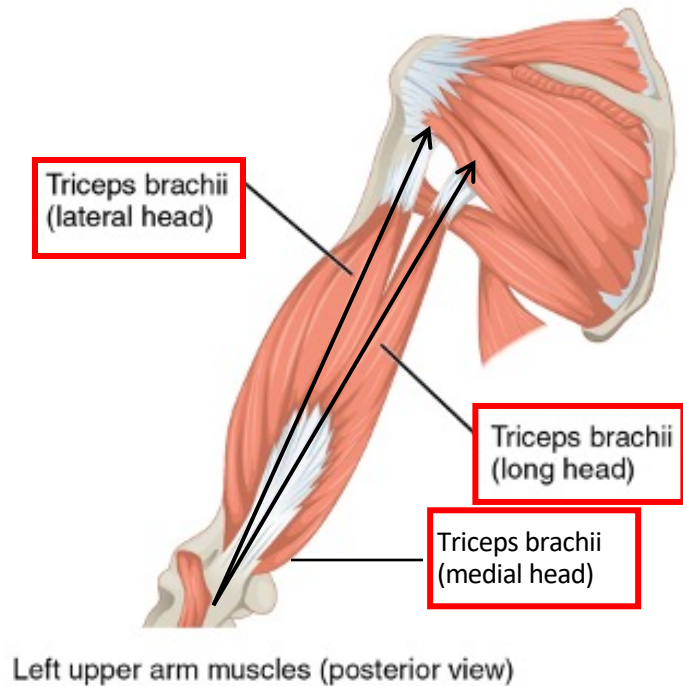


Group 2 & 3: Biceps and Triceps Brachii



Actions:

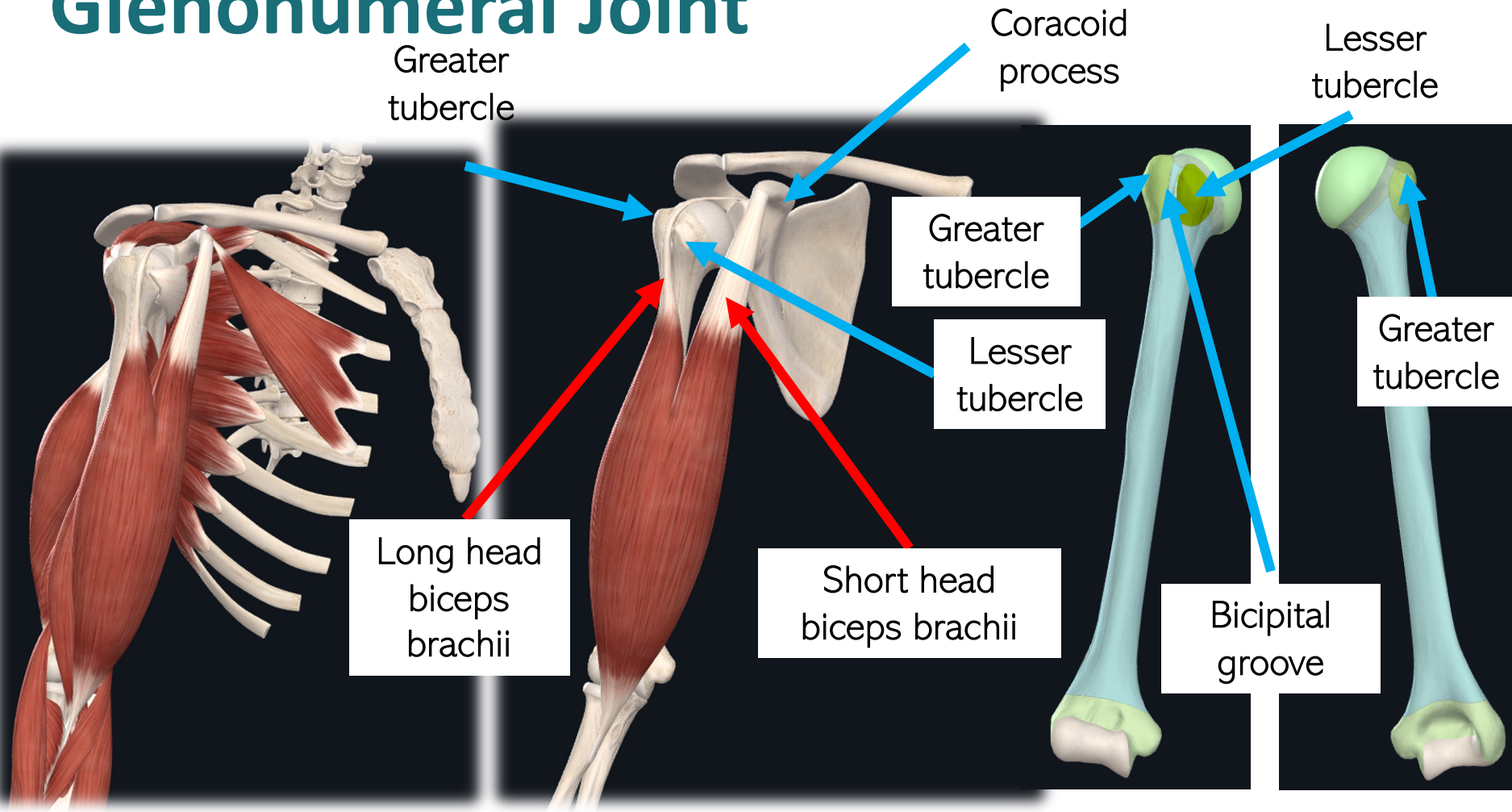
- Flexes forearm
- Flexes arm
- Helps hold humeral head in glenoid fossa (long head only)



Actions:

- Extends forearm
- Adducts arm (long head only as it originates on the scapula)

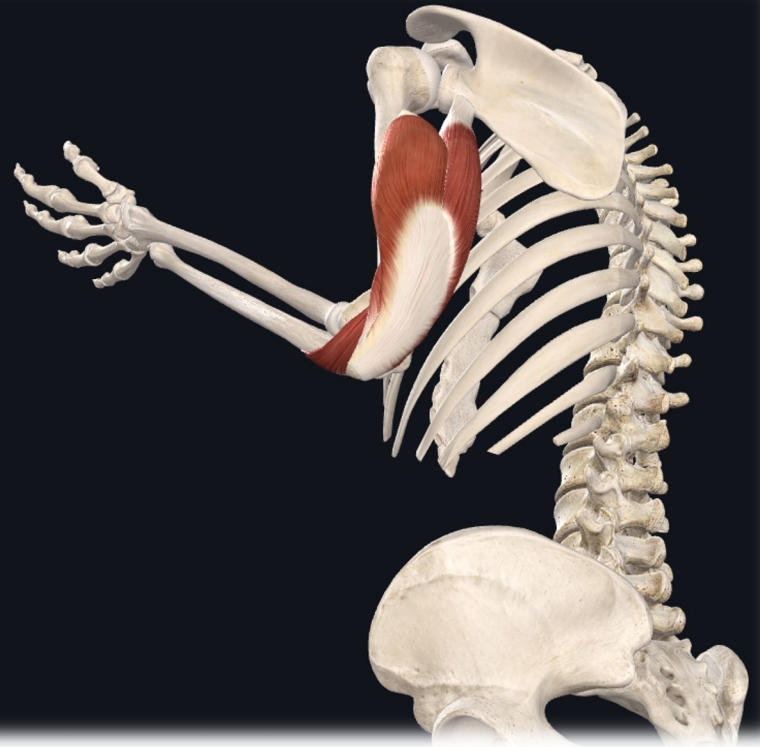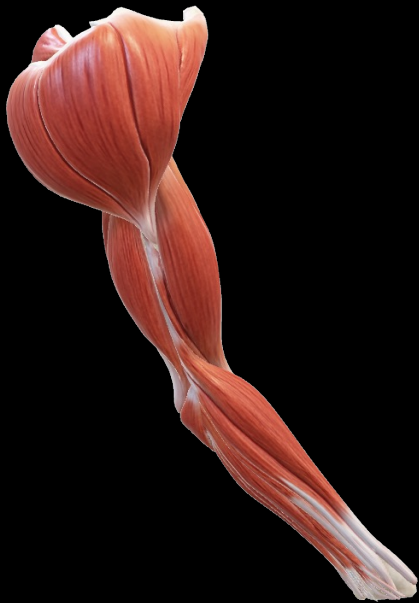
Glenohumeral Joint



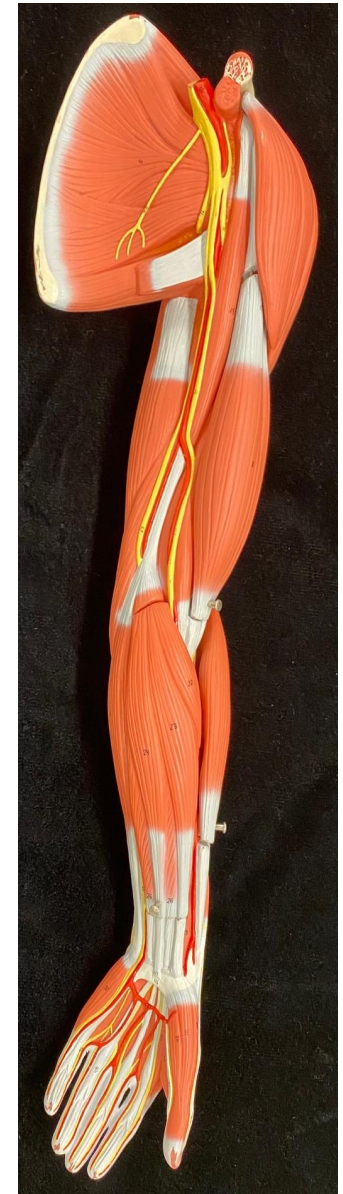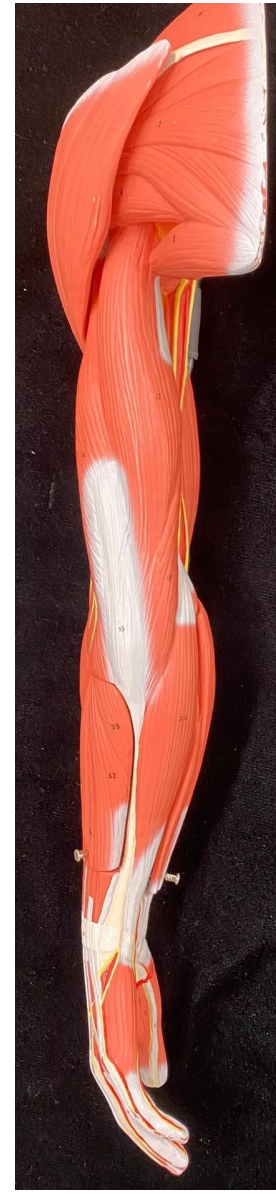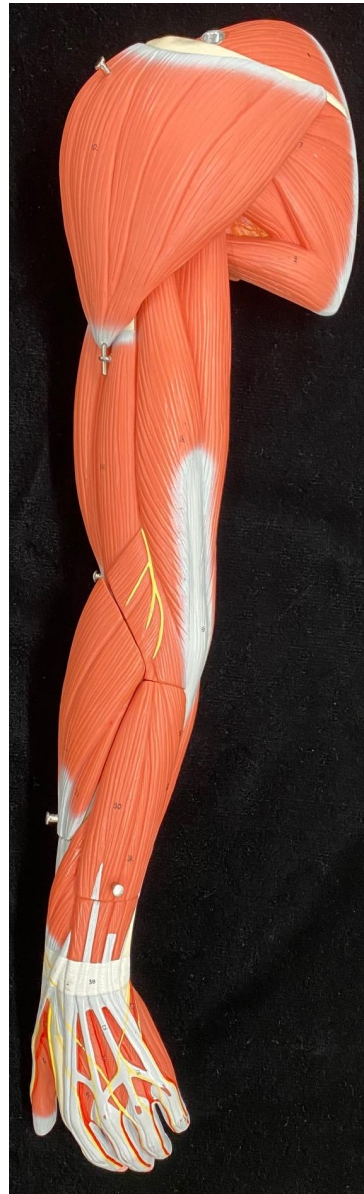ANTERIOR

POSTERIOR

Muscles that Move the Forearm

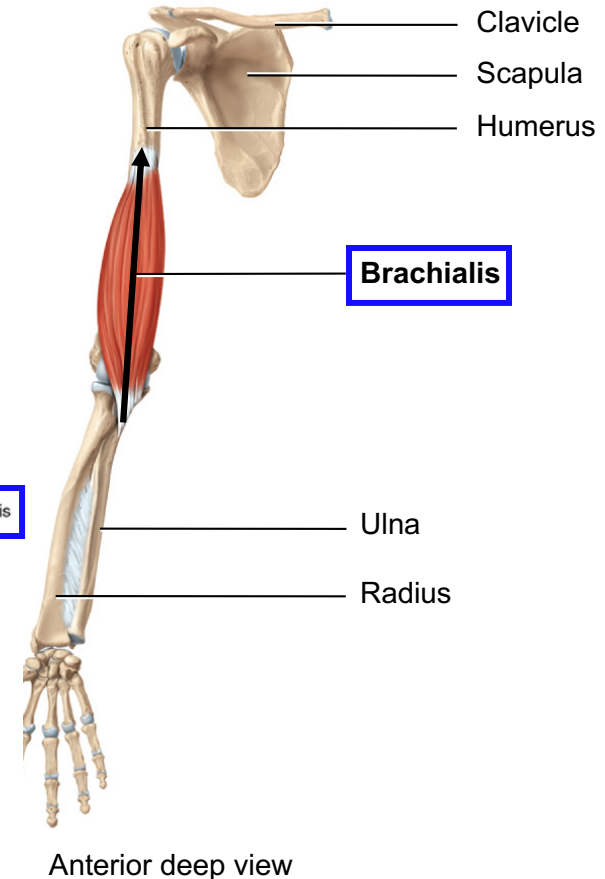
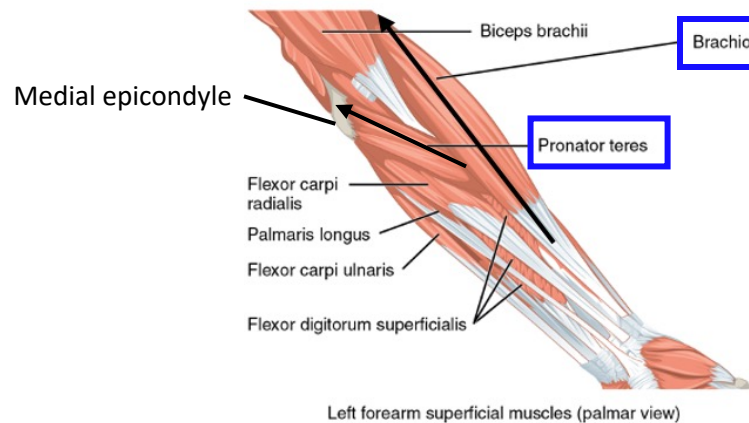
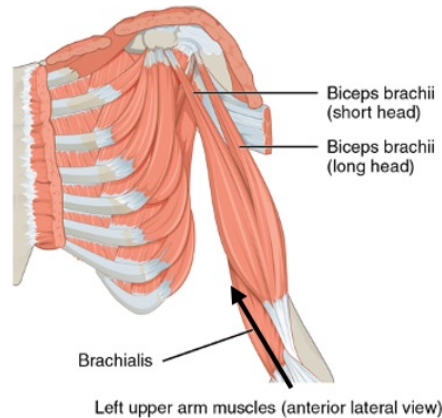
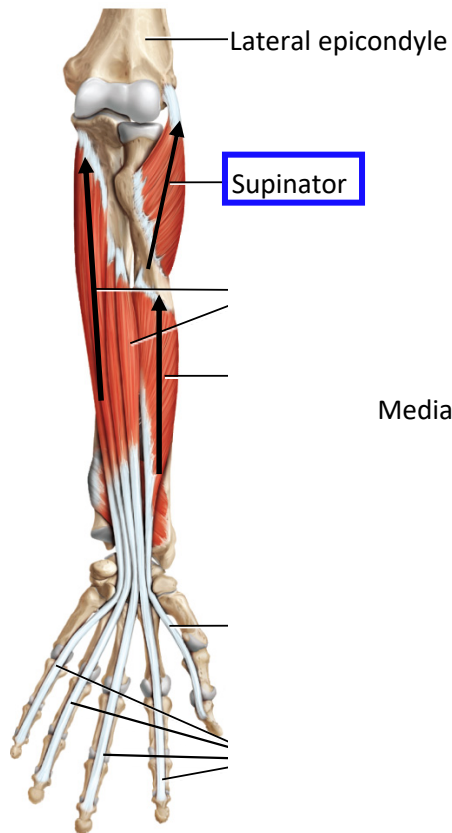


Lab Models

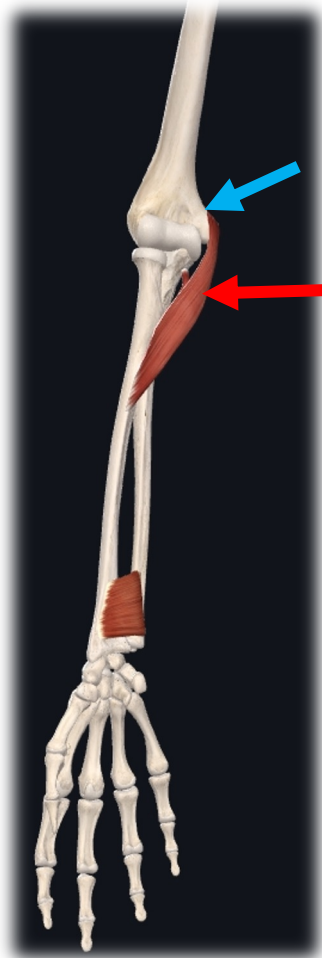


c. Group 3: Move Forearm at Elbow

- **Origin:** Humerus
- **Insertion:** Radius or Ulna

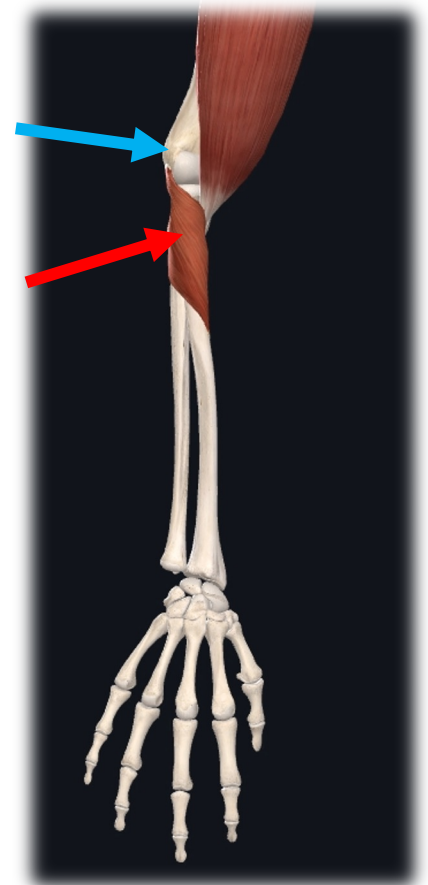


Pronation vs Supination



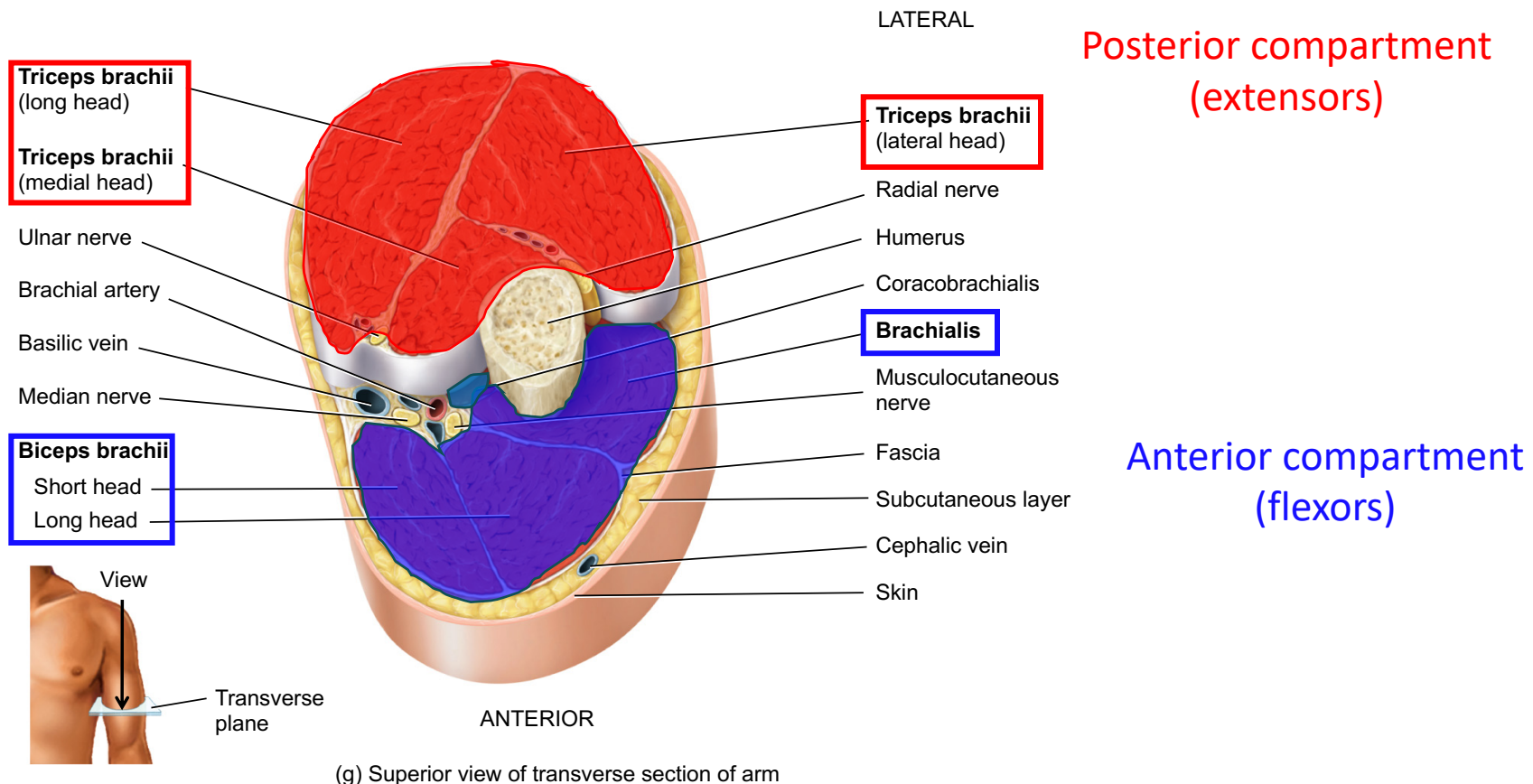
Medial epicondyle of
humerus
pronator
teres

Lateral epicondyle
of humerus
supinator



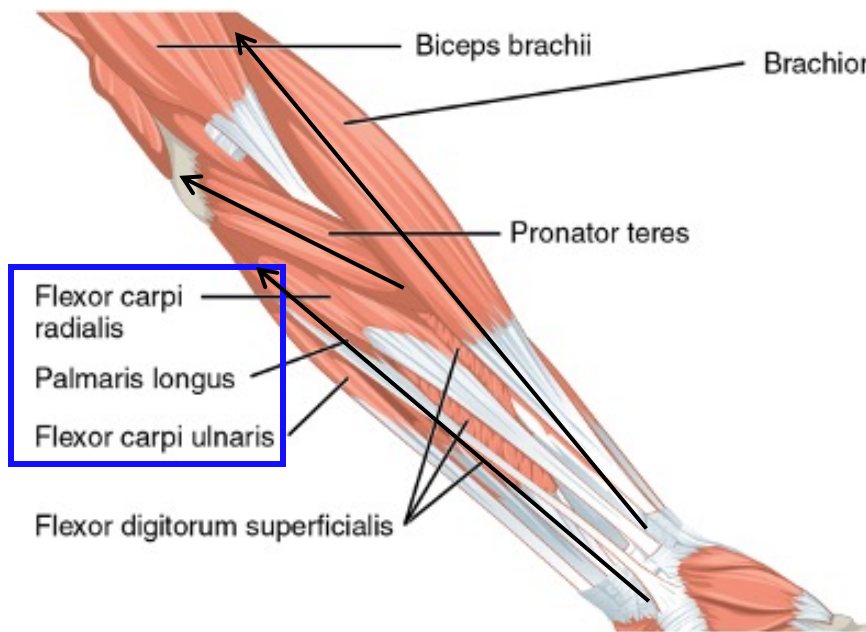
Arm Muscle Compartments

Contains muscles from Groups 2 (muscles that move the arm at shoulder & 3 muscles that move the forearm at the elbow

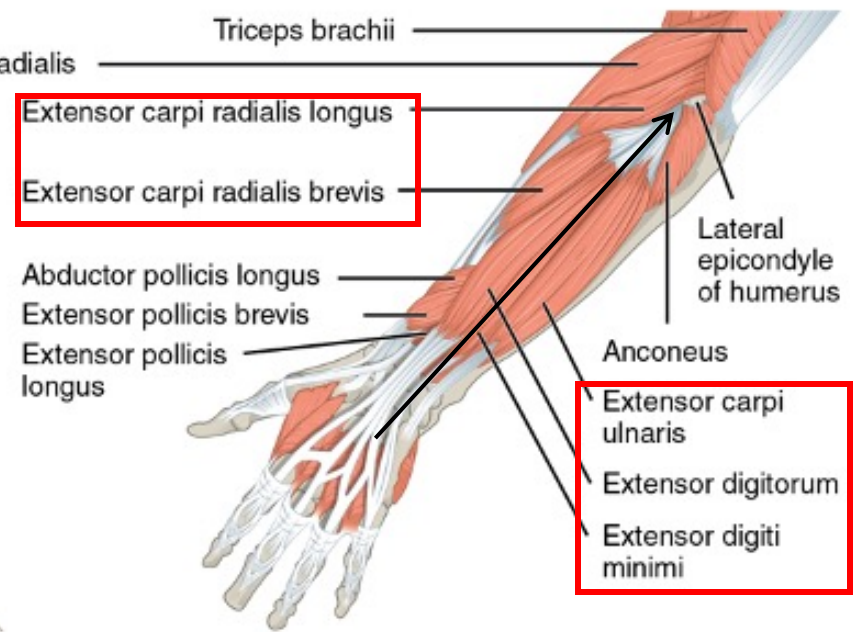


d. Group 4: Move Hand at Wrist

- **Origin:** Humerus, Radius, or Ulna
- **Insertion:** Carpals or Metacarpals

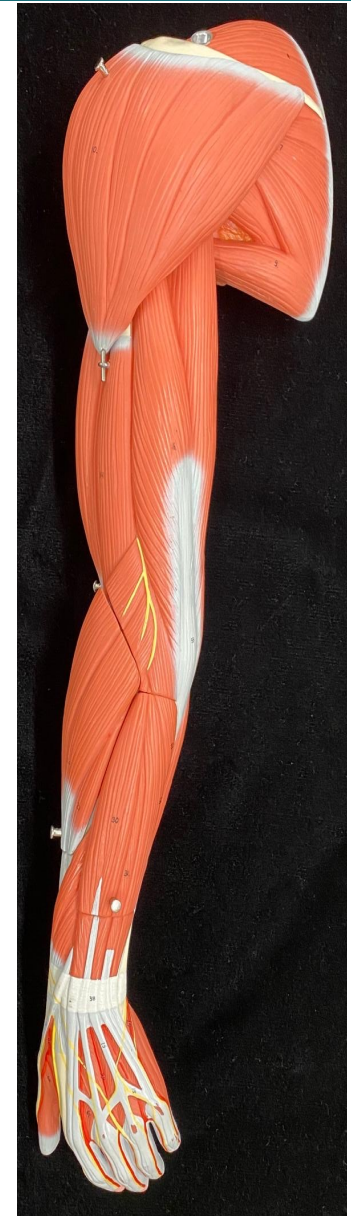
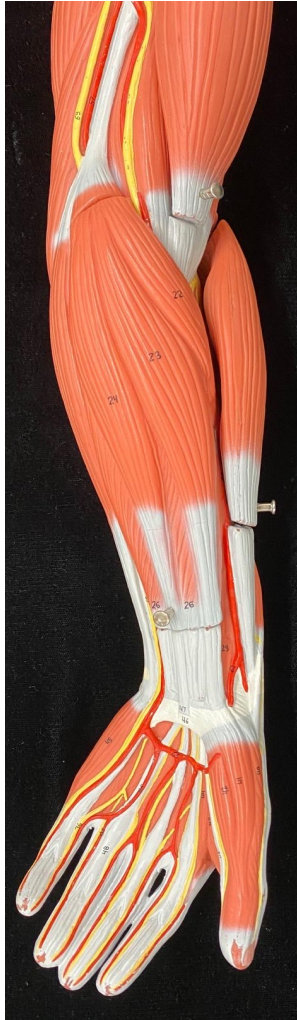

Left forearm superficial muscles (palmar view)



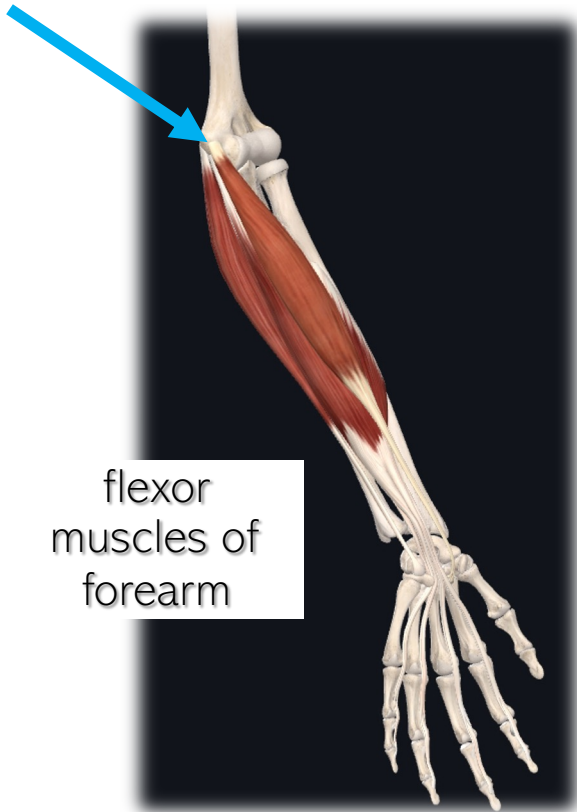
Left forearm superficial muscles (dorsal view)

Lab Models



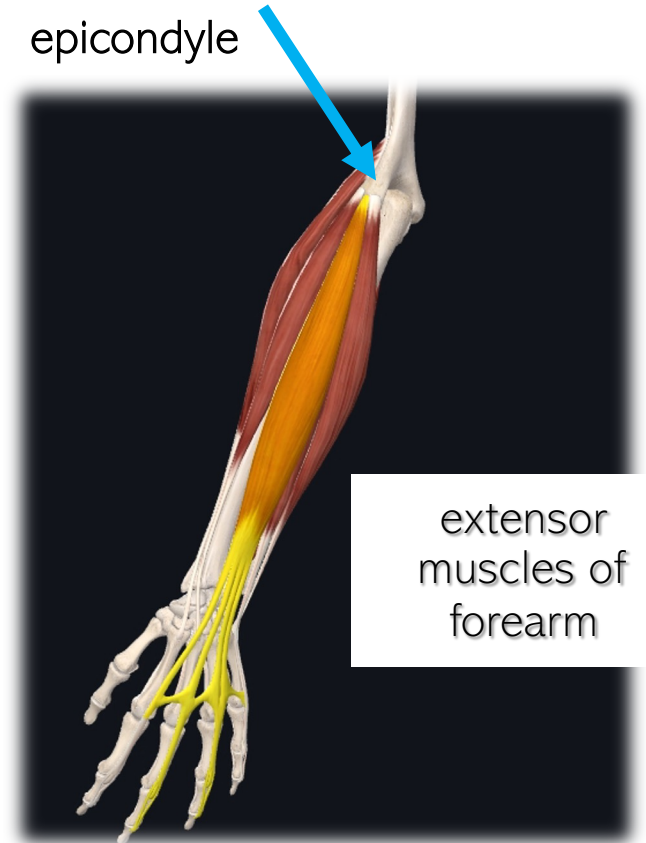
Epicondyles of Humerus as Attachment Points

Medial
epicondyle



flexor
muscles of
forearm

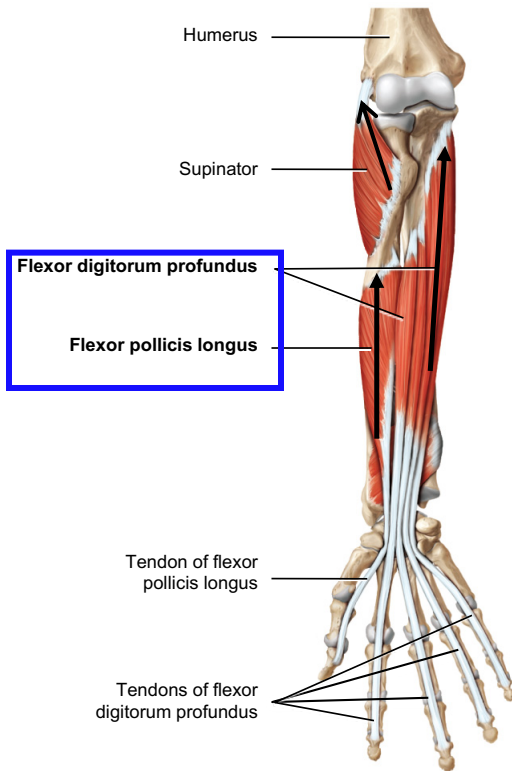
Lateral
epicondyle



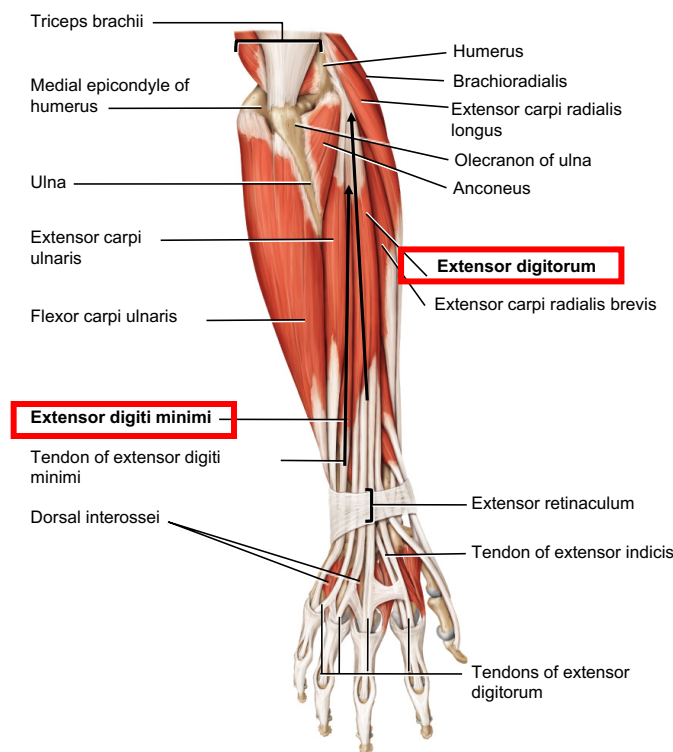
extensor
muscles of
forearm

e. Group 5: Move Digits

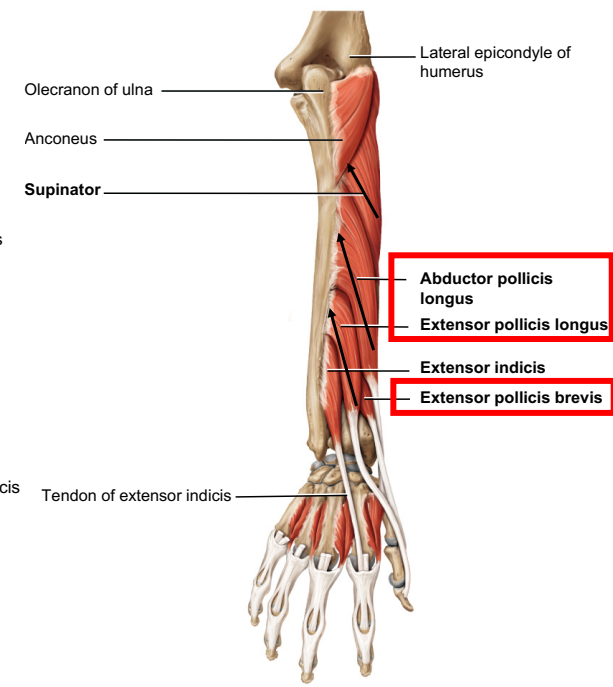
- **Origin:** Radius or Ulna
- **Insertion:** Phalanges



(c) Anterior deep view



(g) Posterior superficial view



(h) Posterior deep view

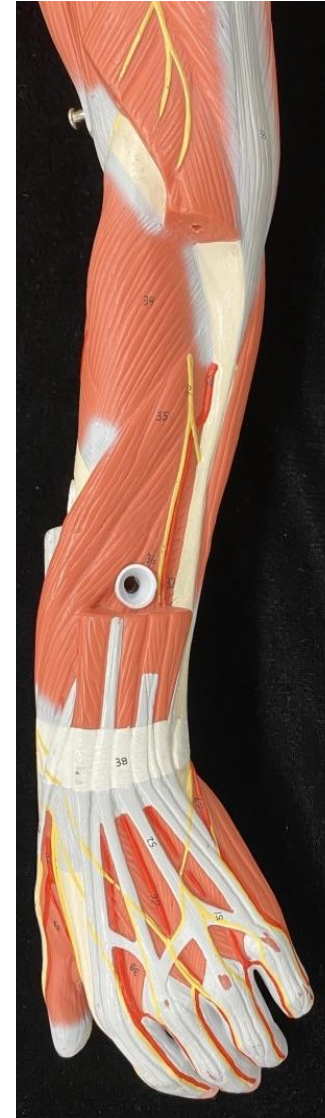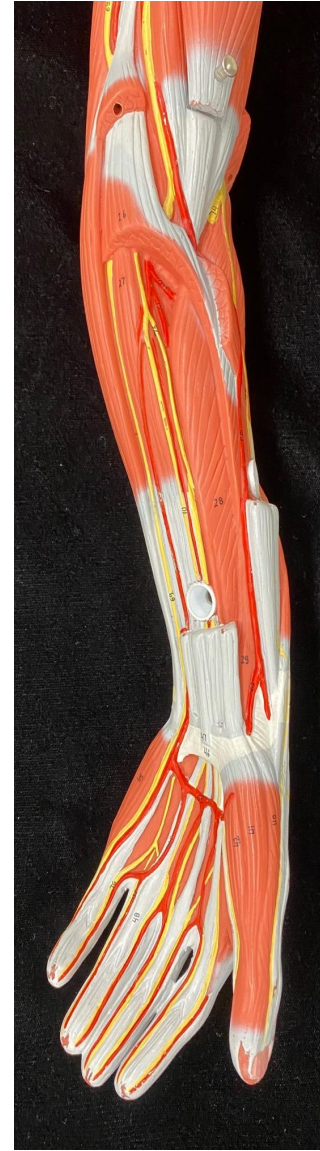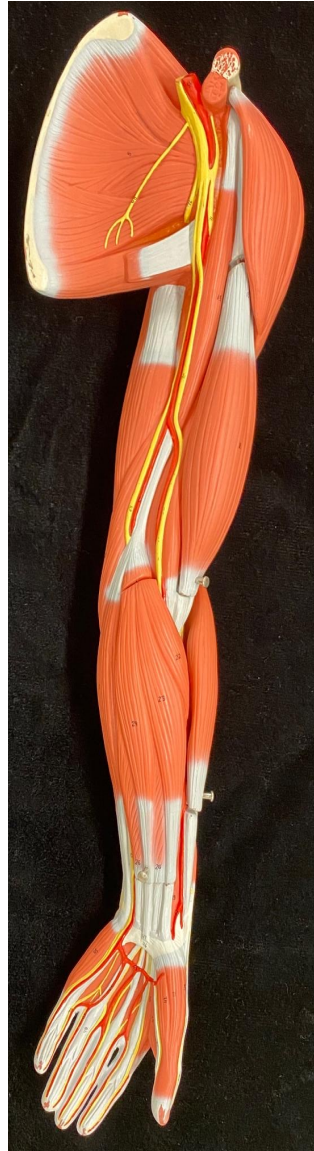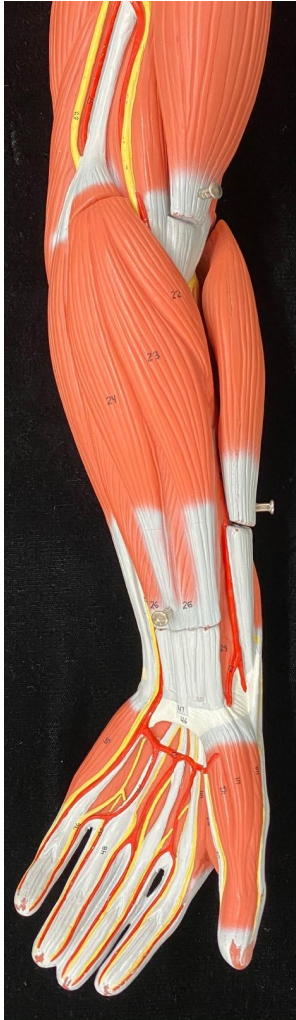ANTERIOR

ANTERIOR

ANTERIOR

POSTERIOR

Lab Models



Forearm Muscle Compartments

Contains muscles from Groups 4 (muscles that move the hand at wrist) & 5 mostly (muscles that move the digits)

Posterior compartment
(extensors)

Radius

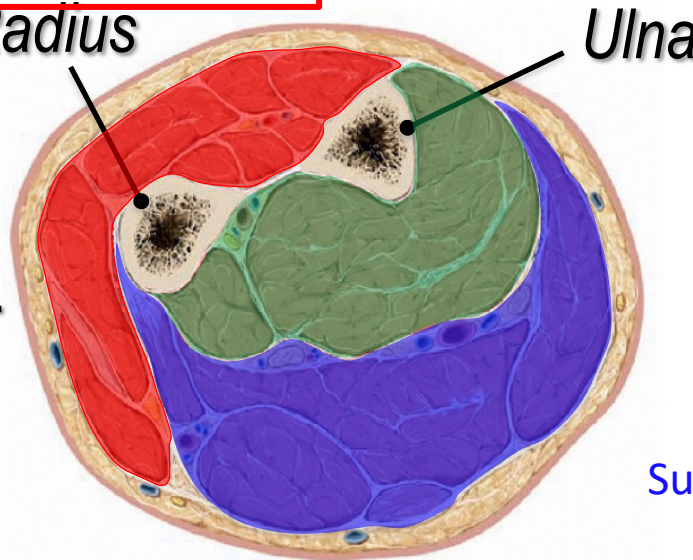
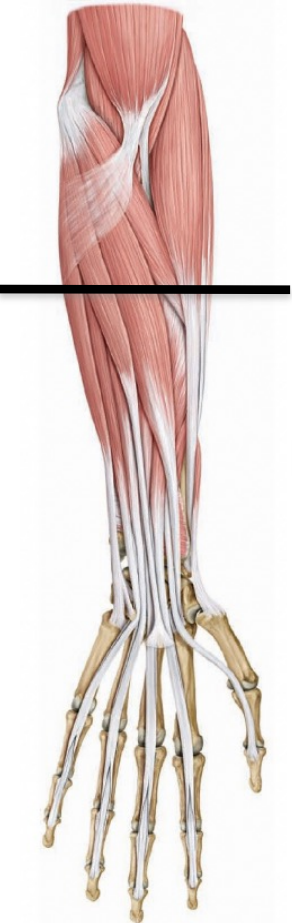Ulna

Deep anterior
compartment
(flexors)

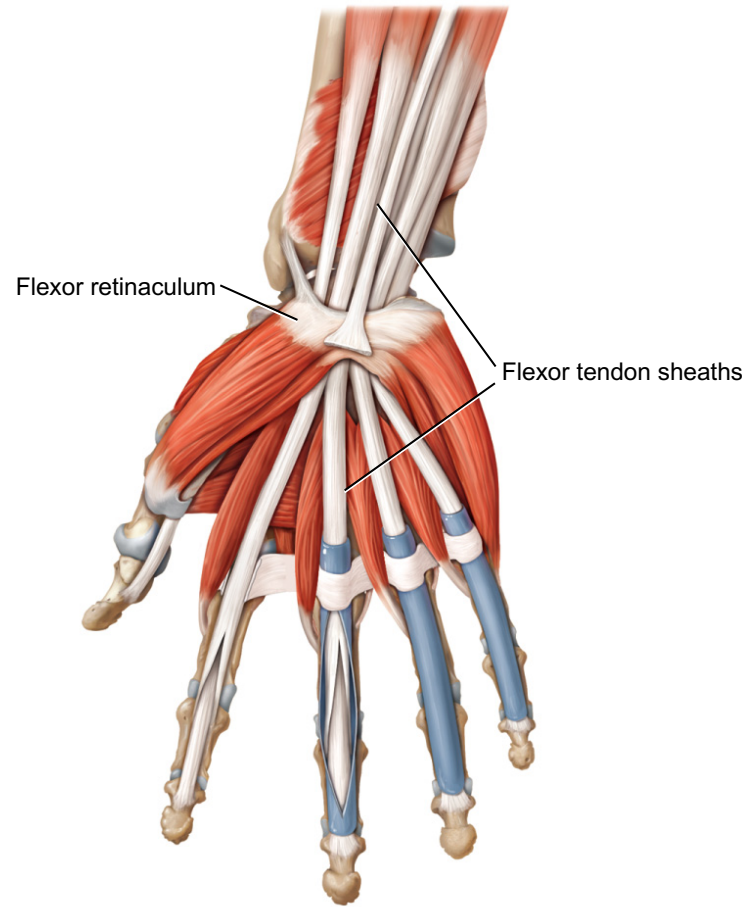
LATERAL

MEDIAL

Superficial anterior compartment
(flexors)



Tendon sheaths and ligaments at wrist



(b) Anterior superficial view